

## **Liver Update Meeting – Nottingham Nov 14 2006**

### **Case Presentation**

Female, born 1978

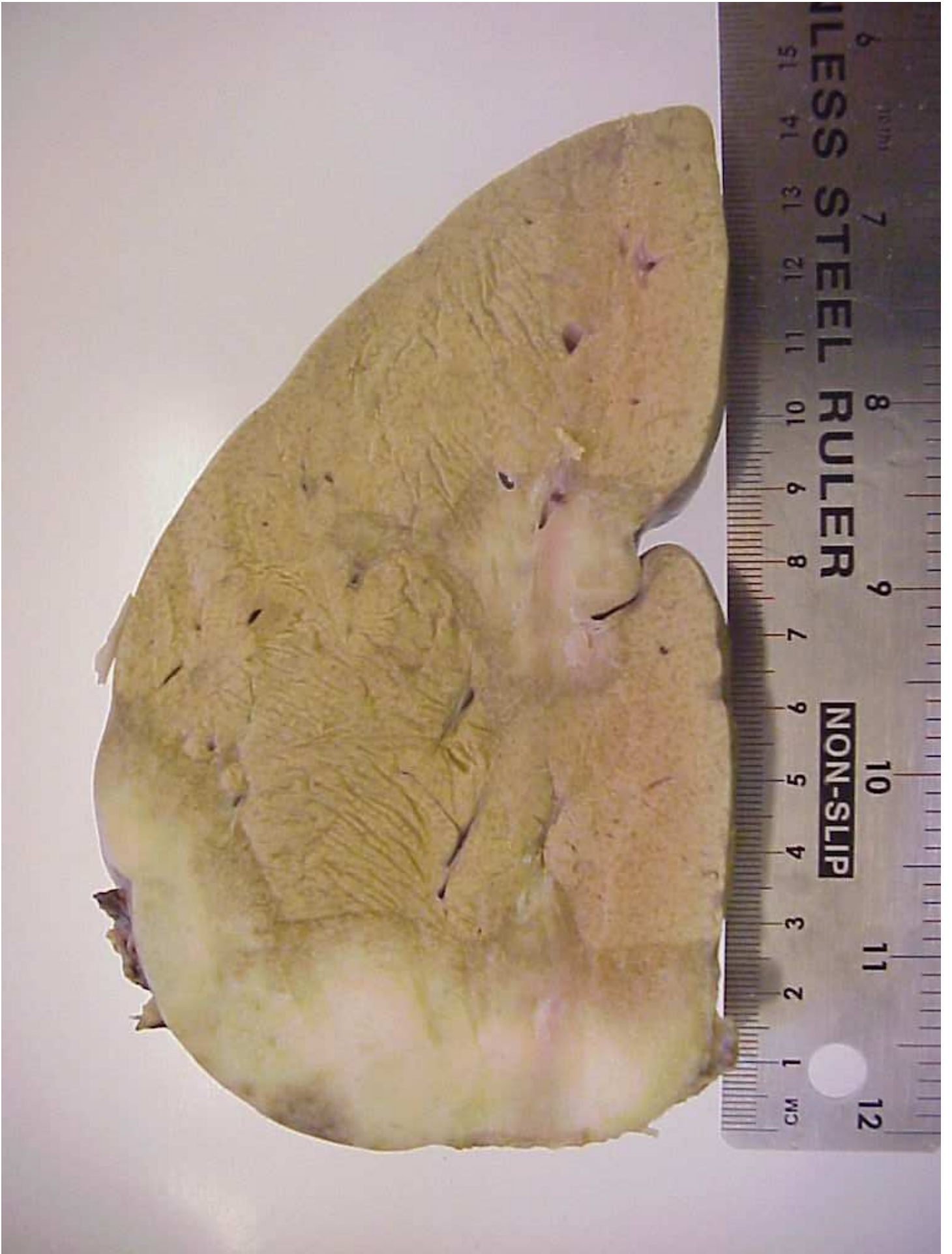Presented in 2002 with multiple liver lesions ?nature

Oral contraceptive pill use. No other medical history

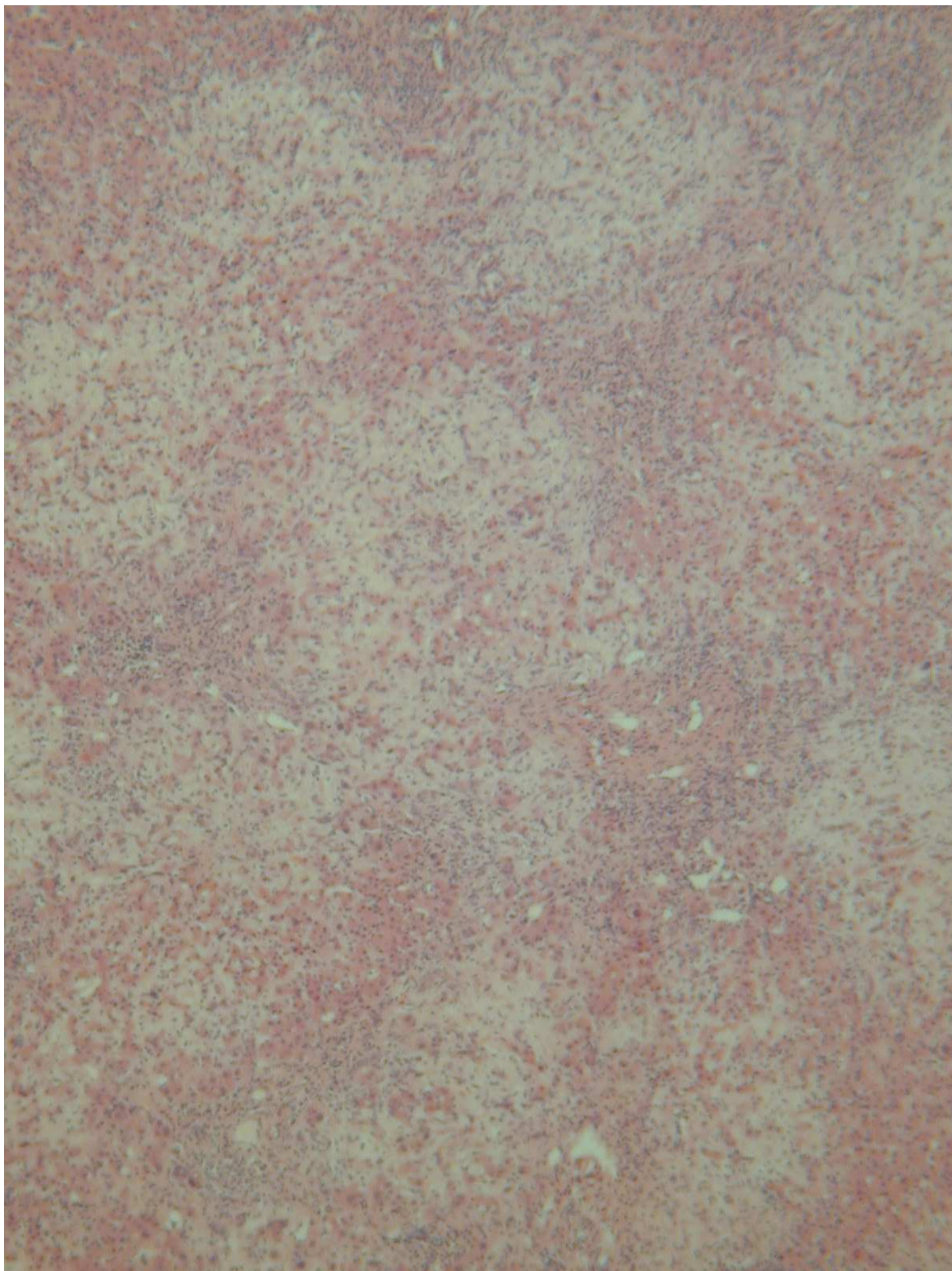
Liver biopsy – fibrosis?cause

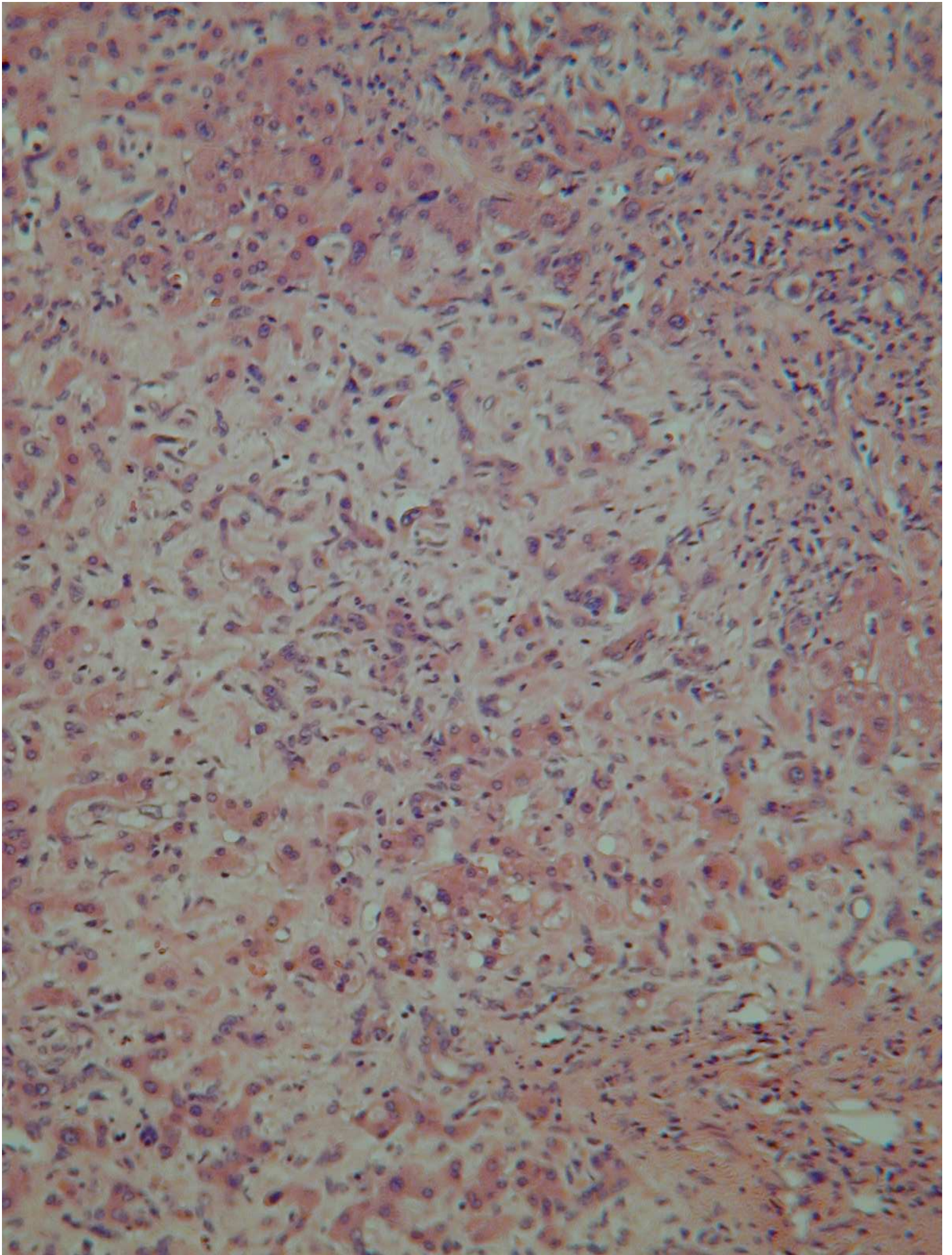
Liver transplantation September 2003

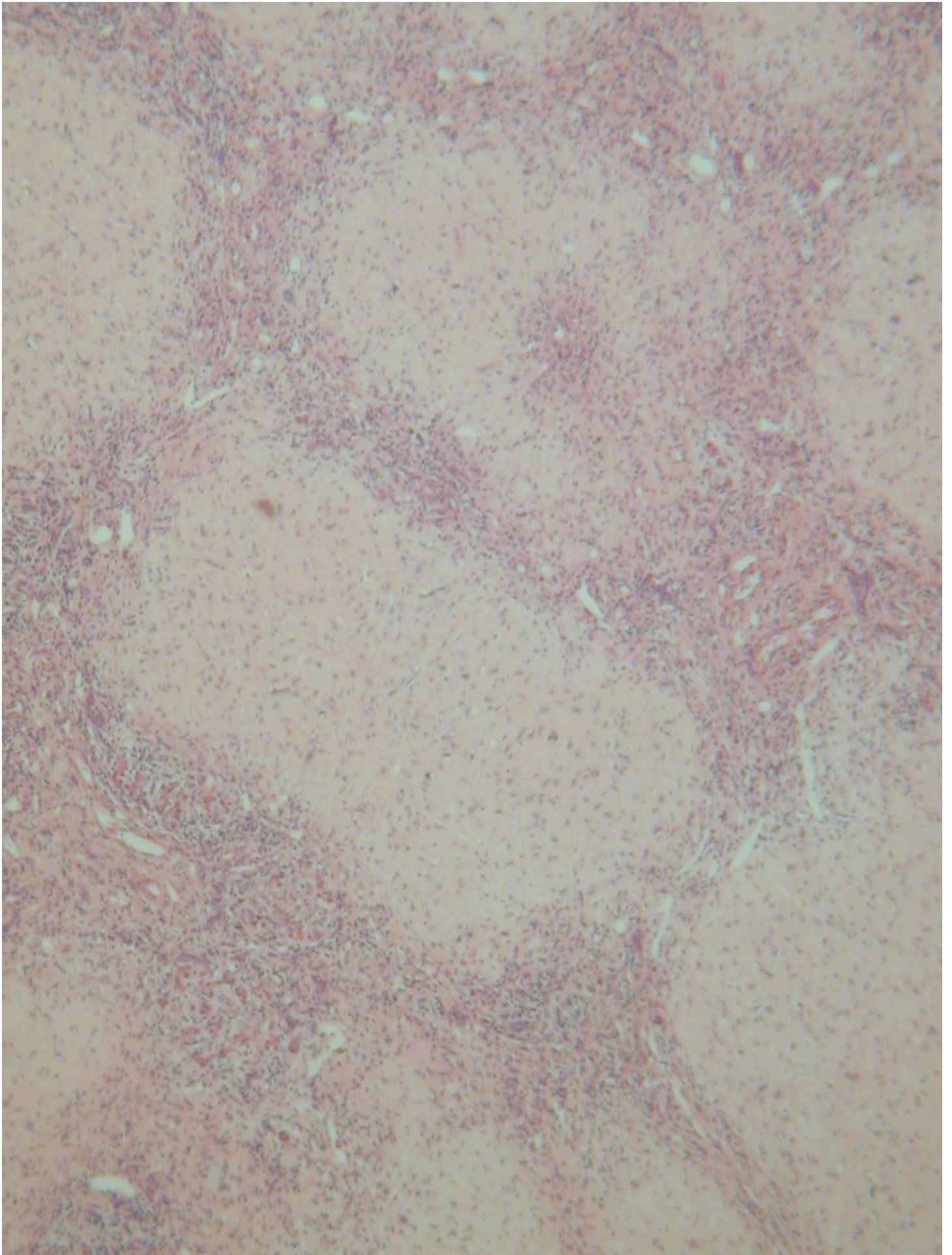
- 13 ill-defined masses throughout liver
- 1-6cm in maximum dimension
- firm, white

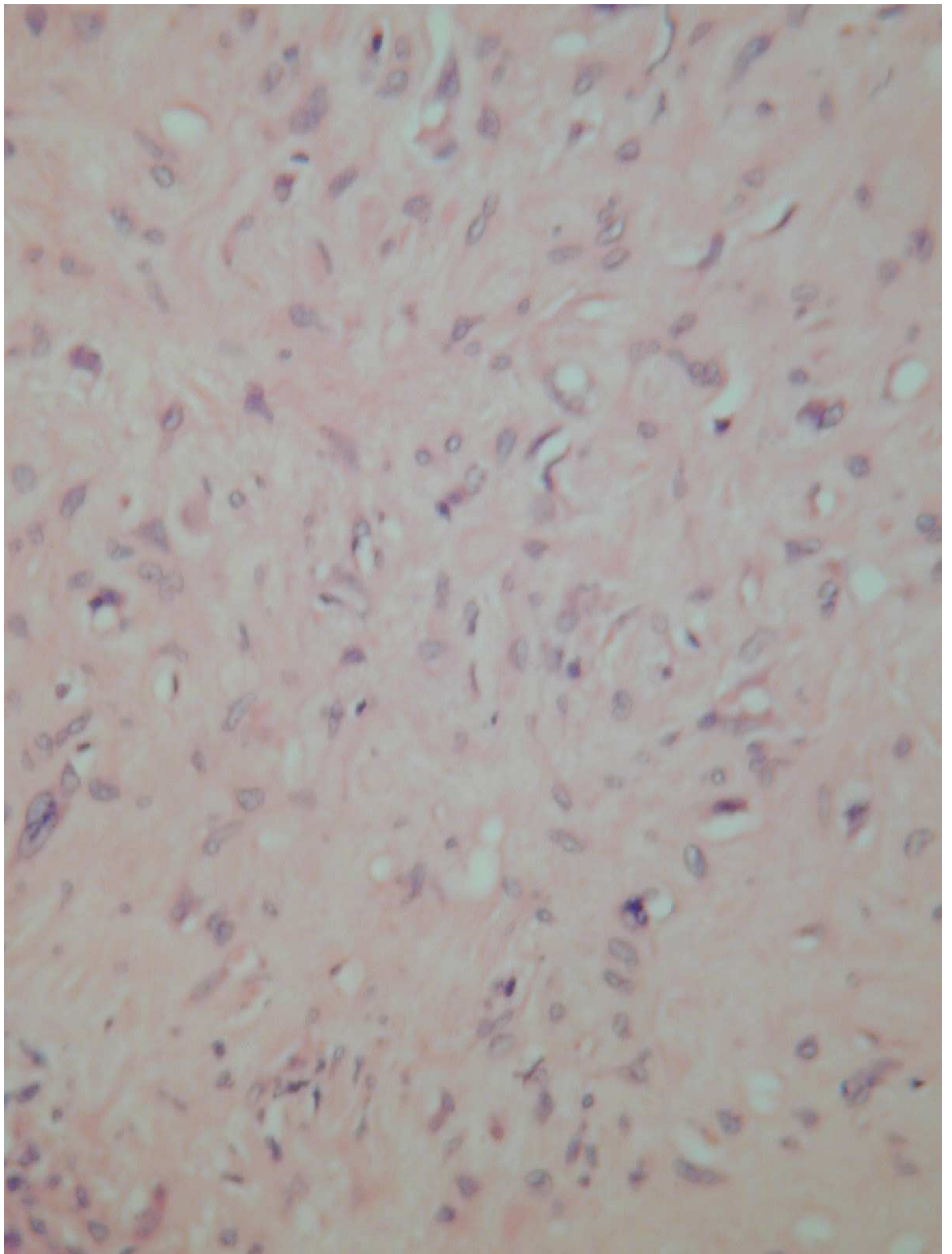


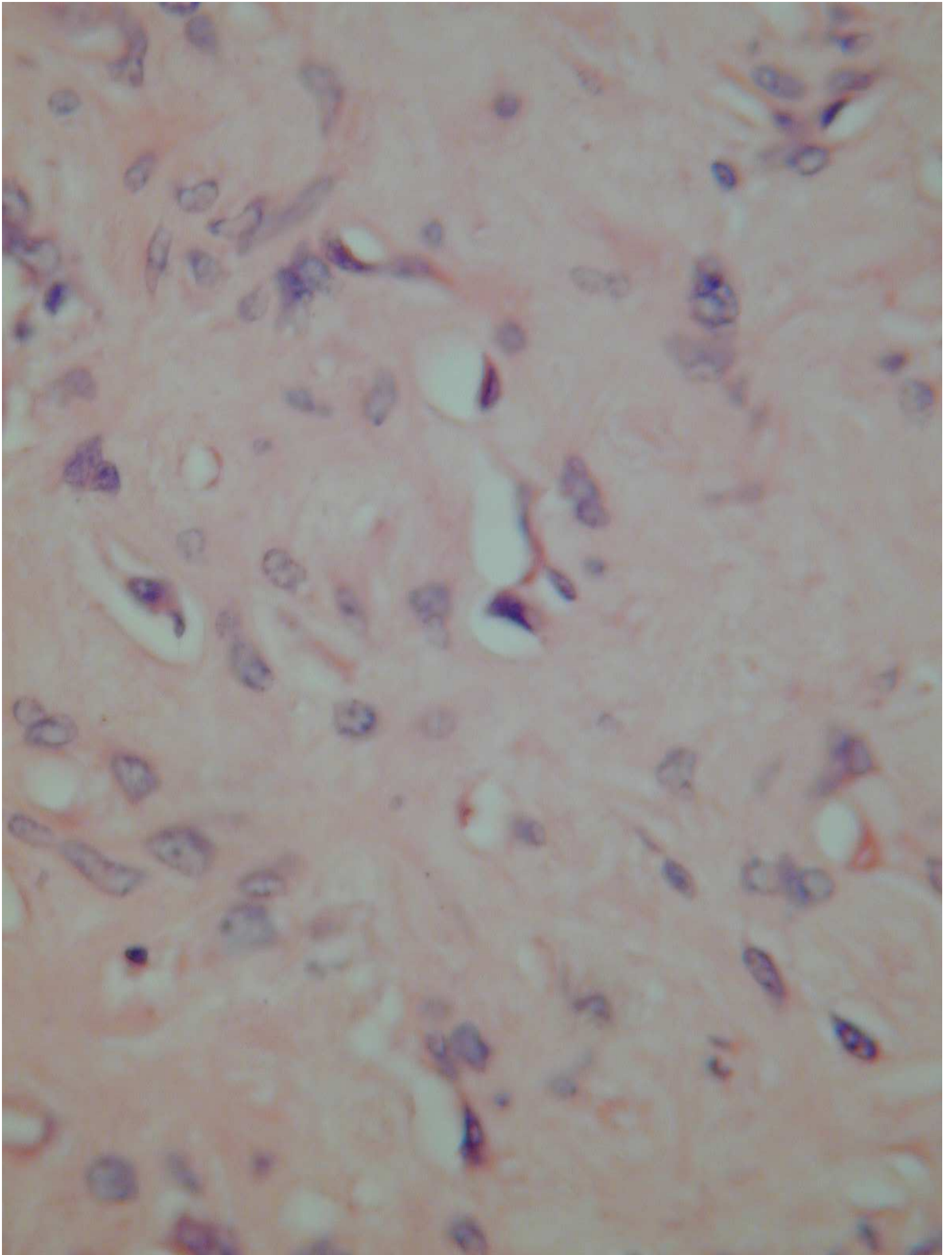
Is this process reactive or neoplastic?

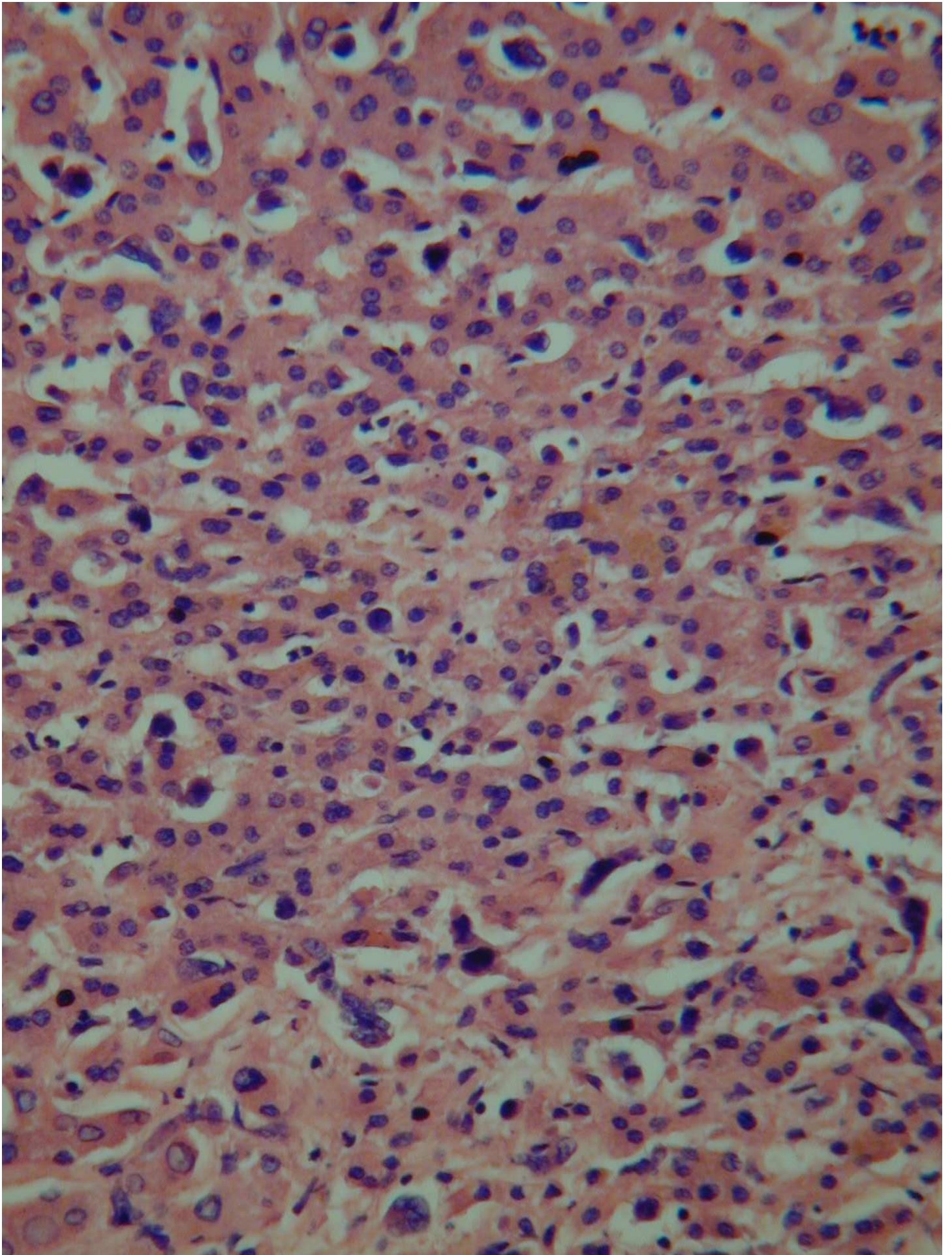


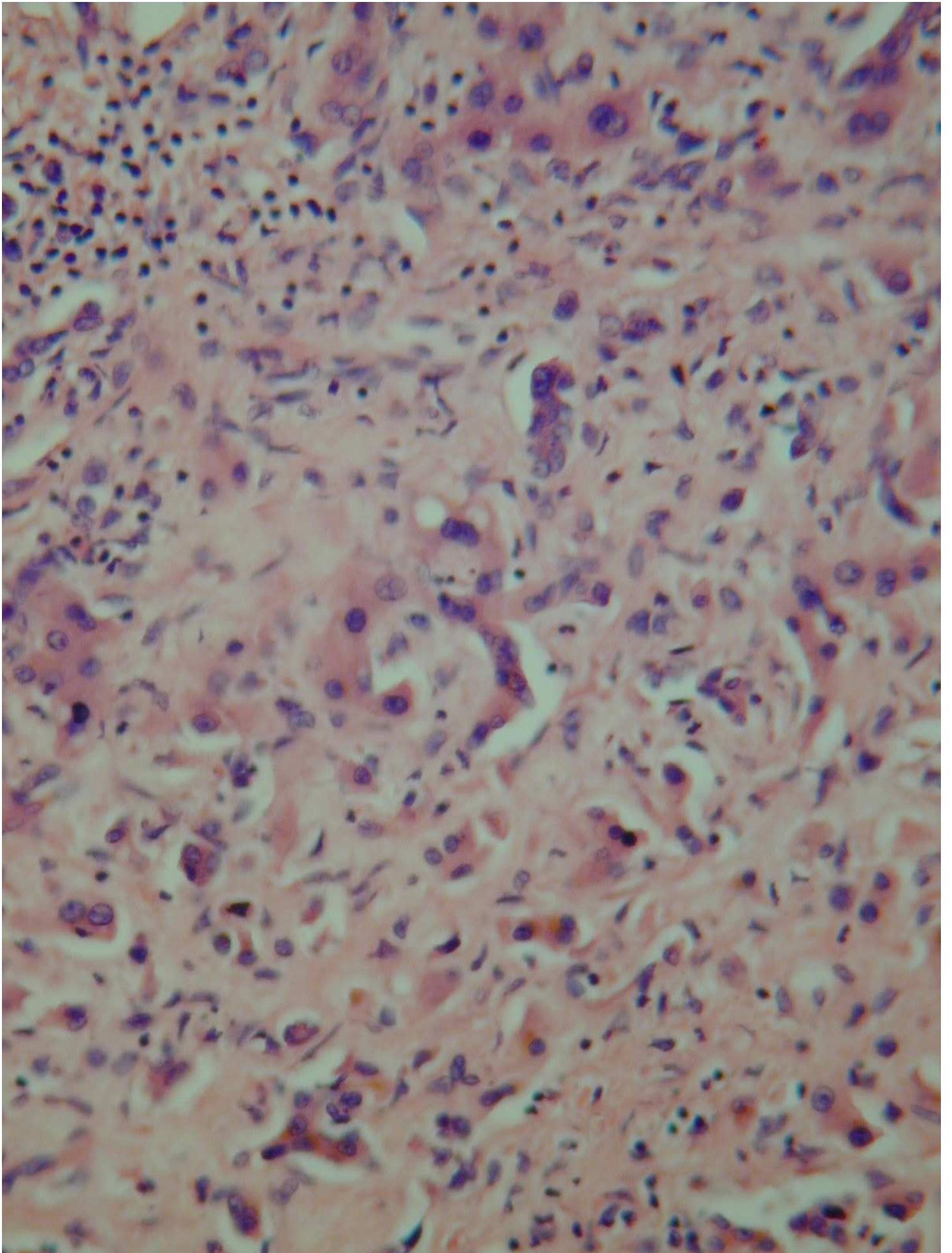


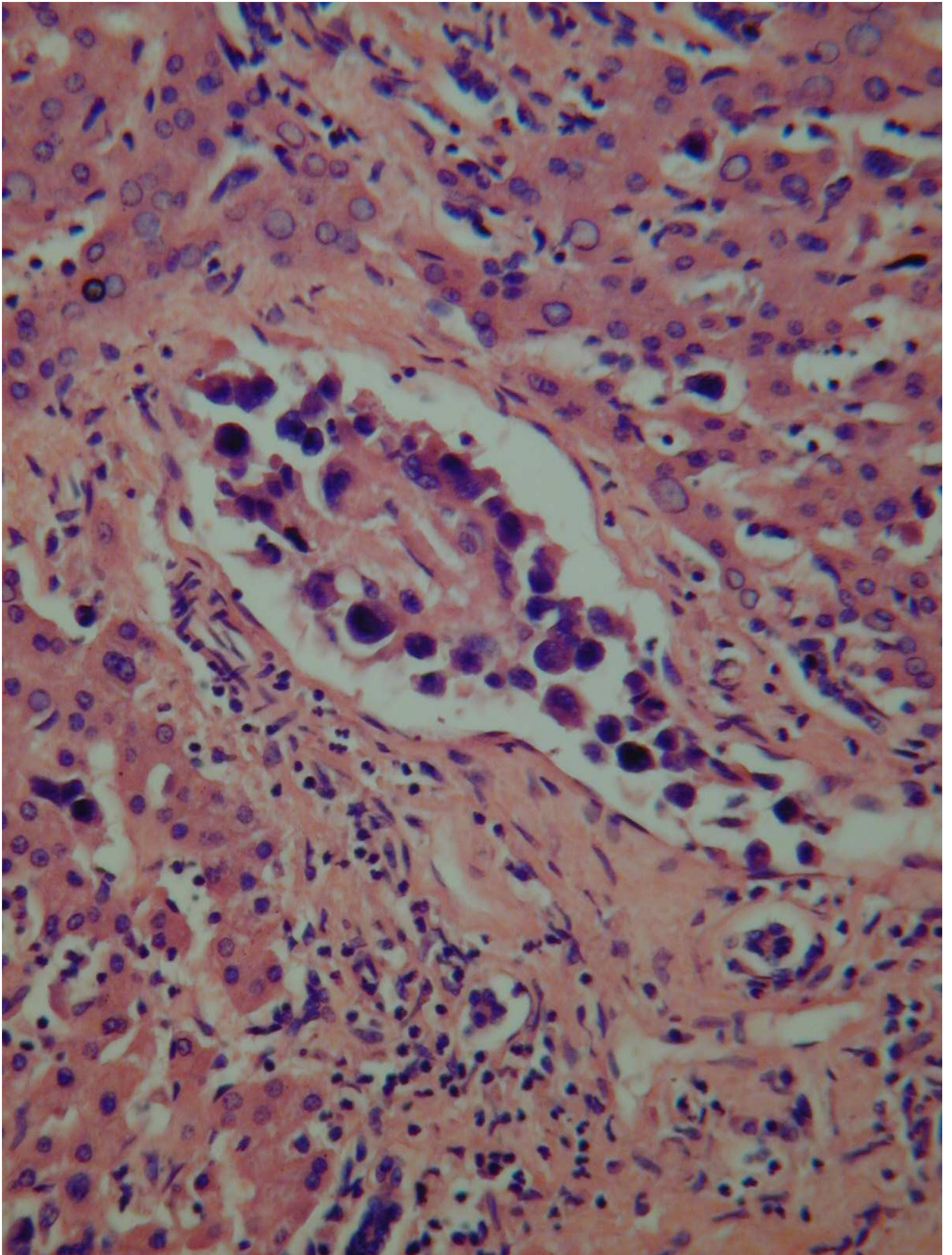


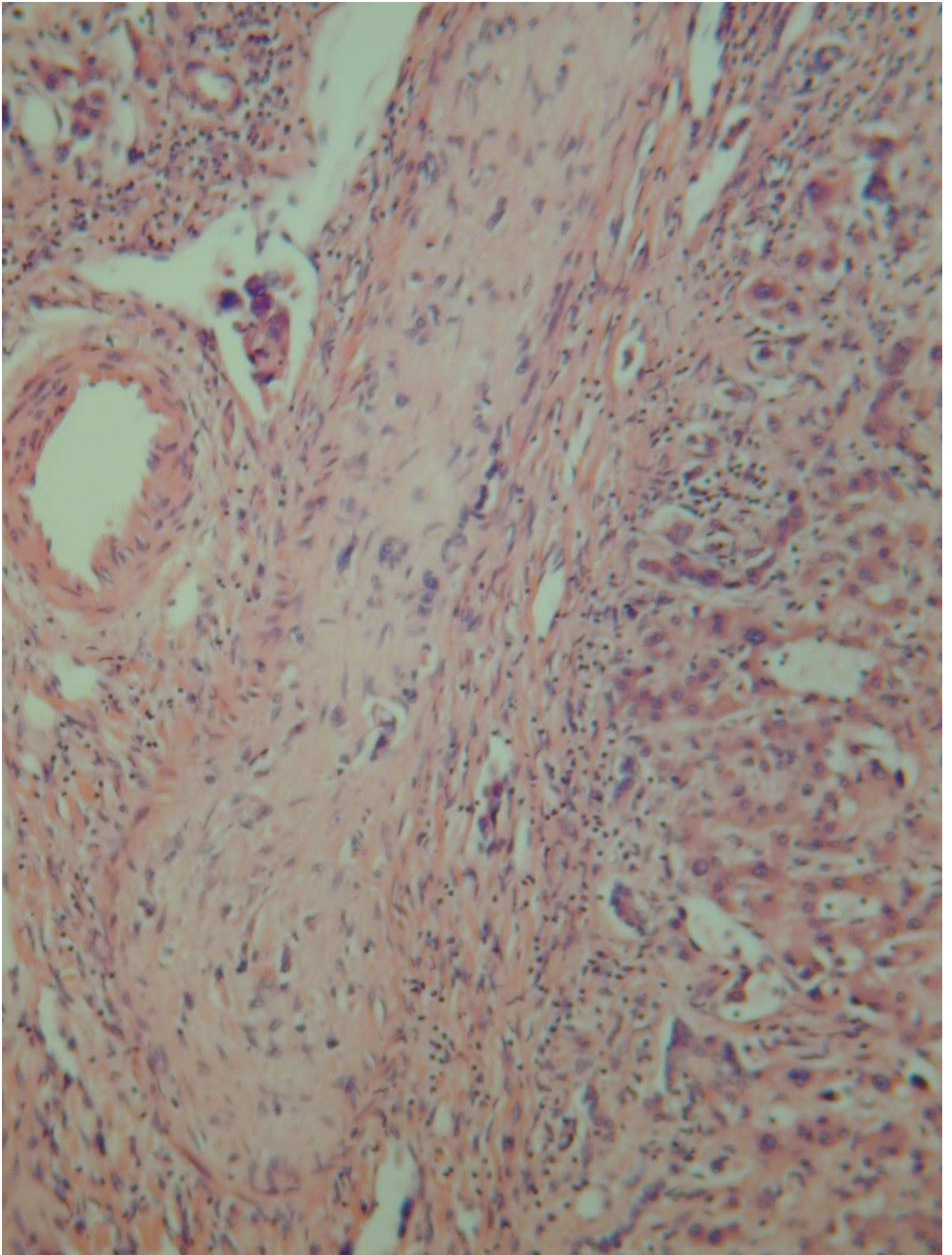


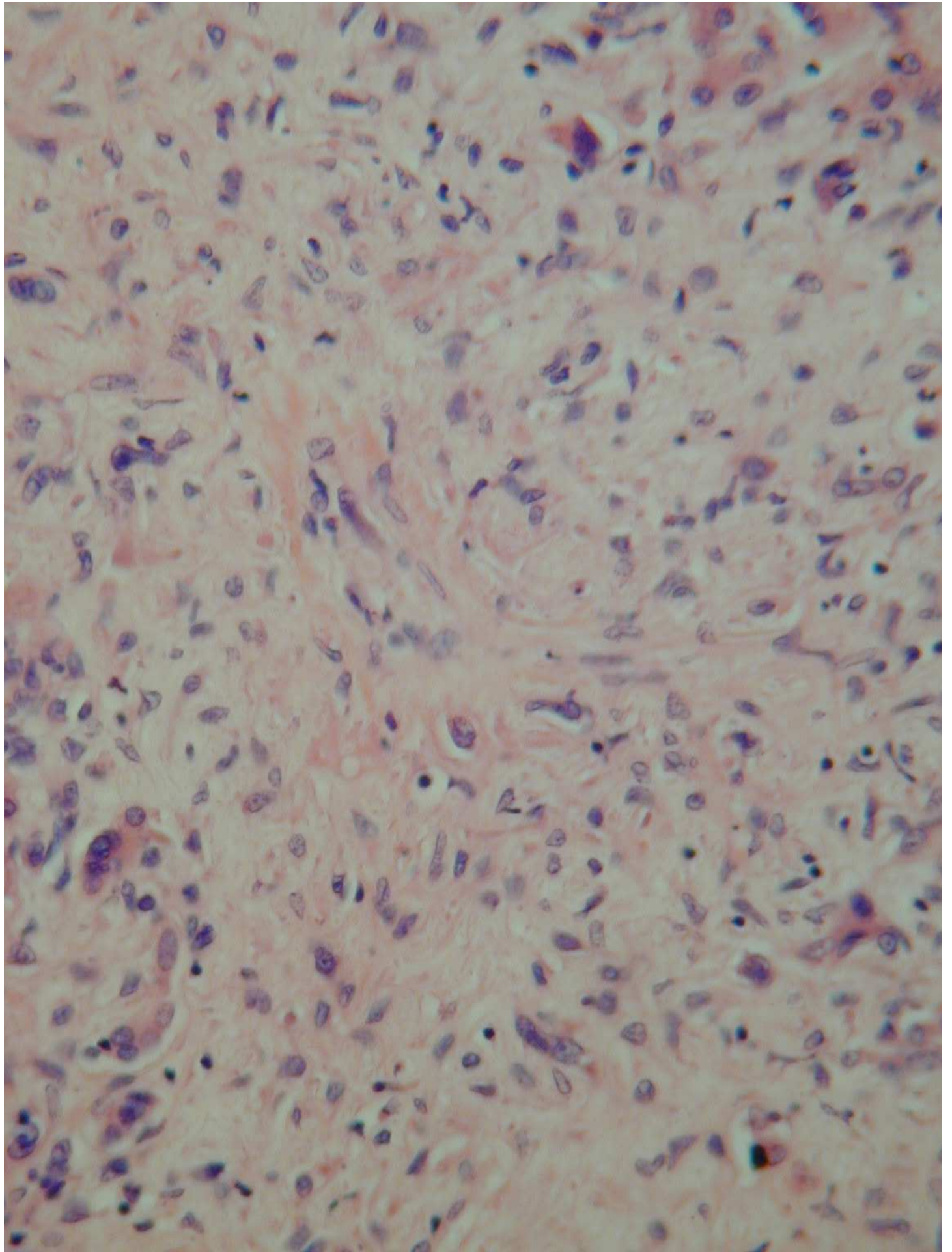


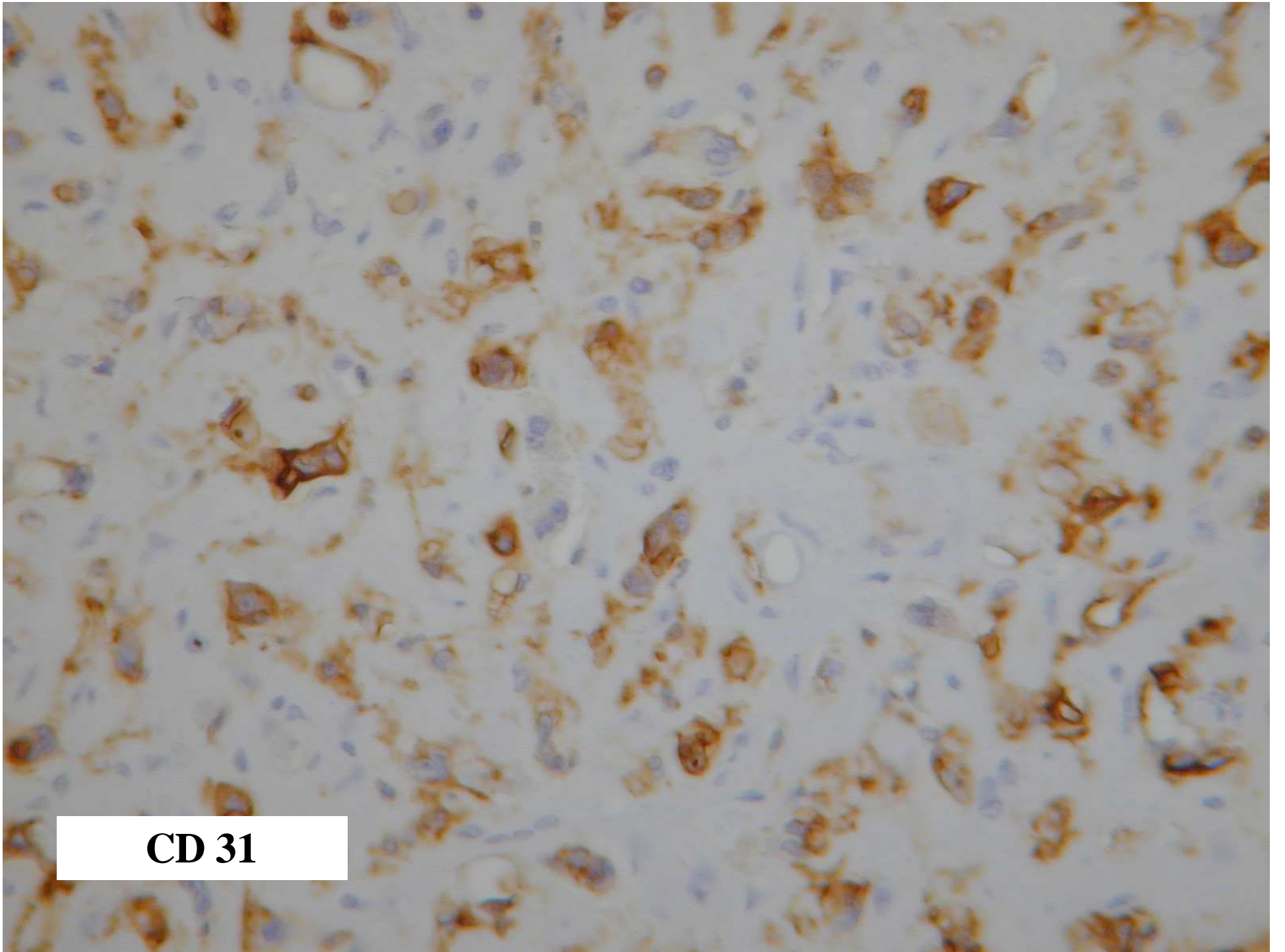




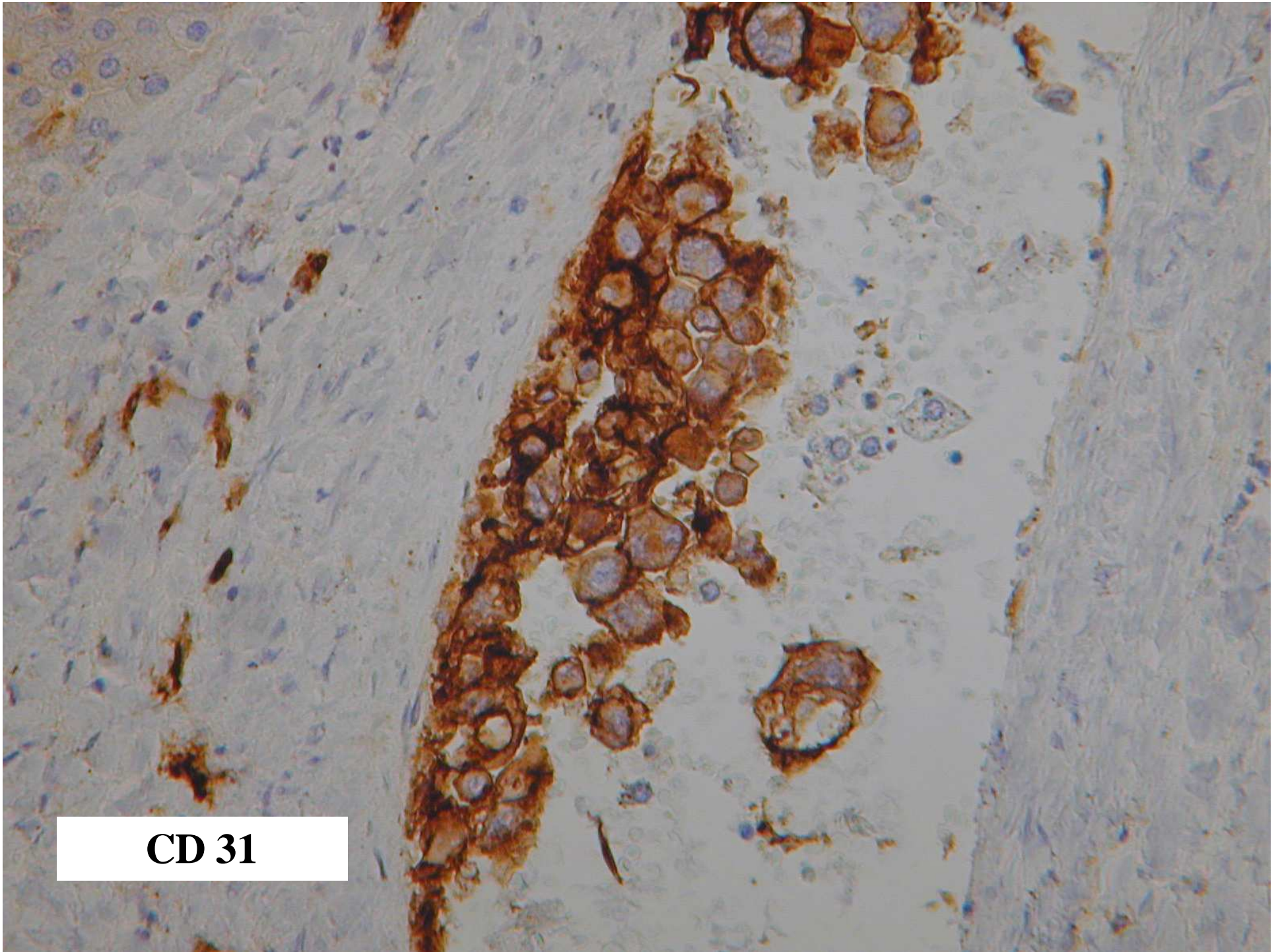




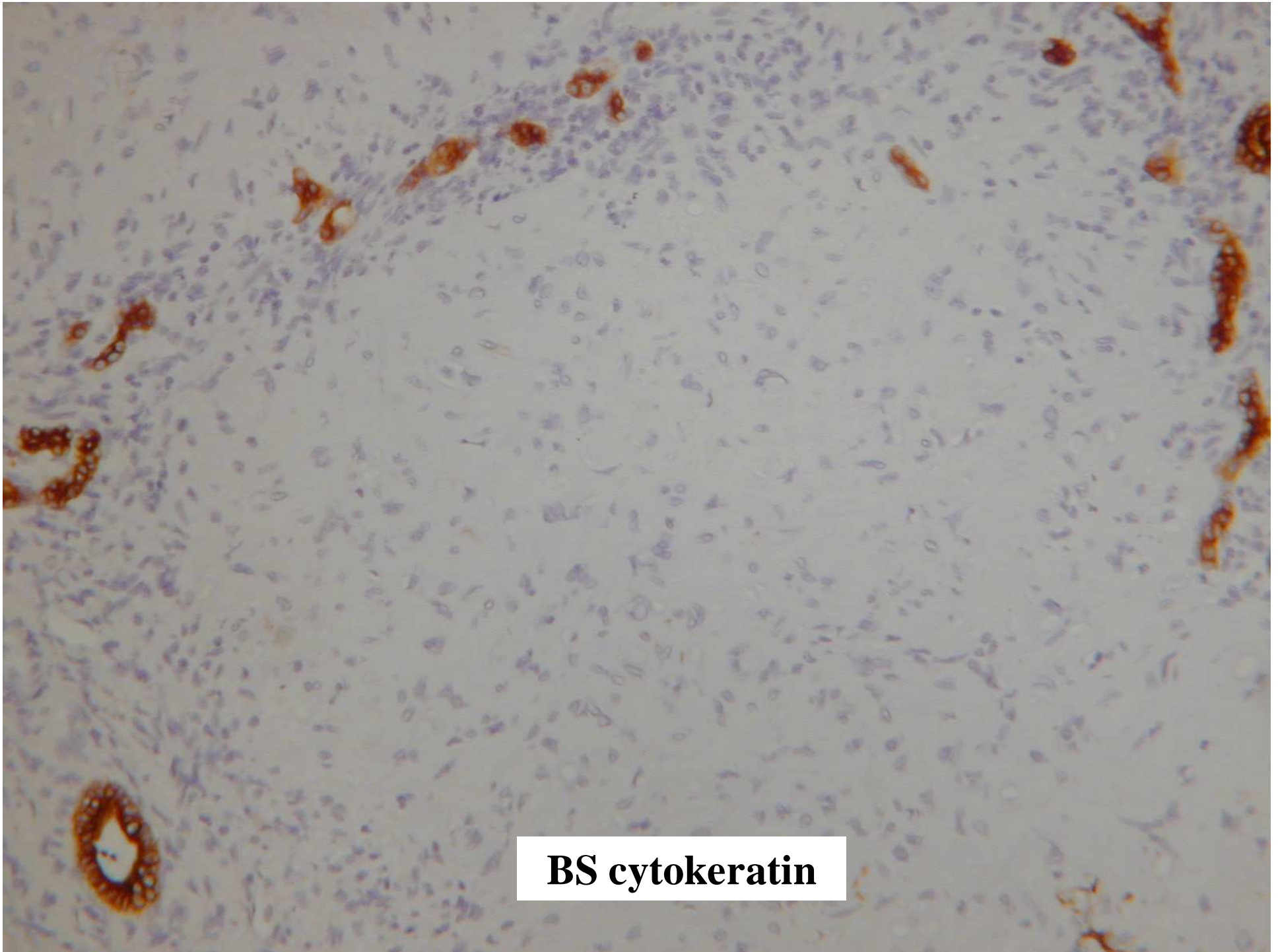




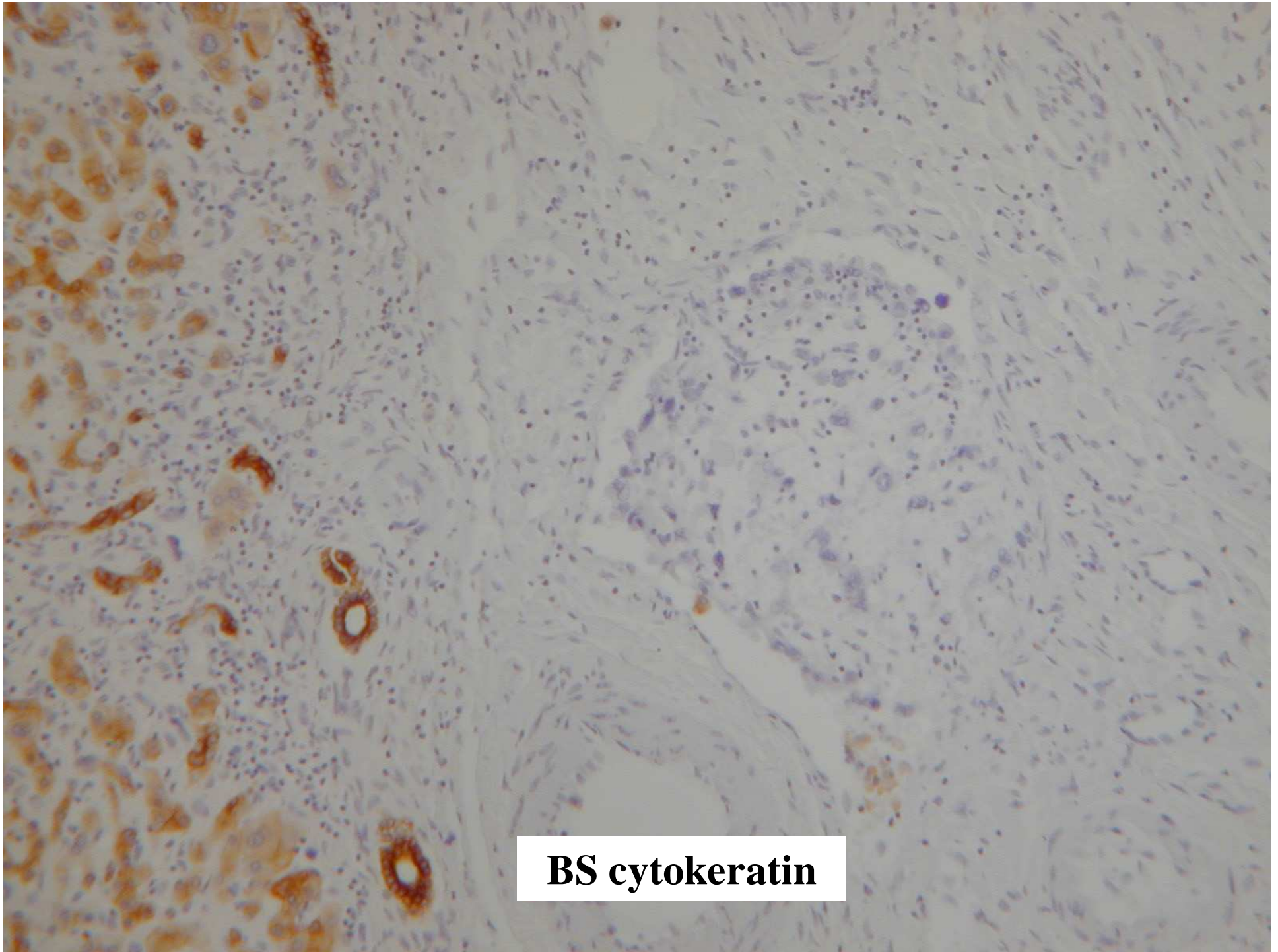
**CD 31**



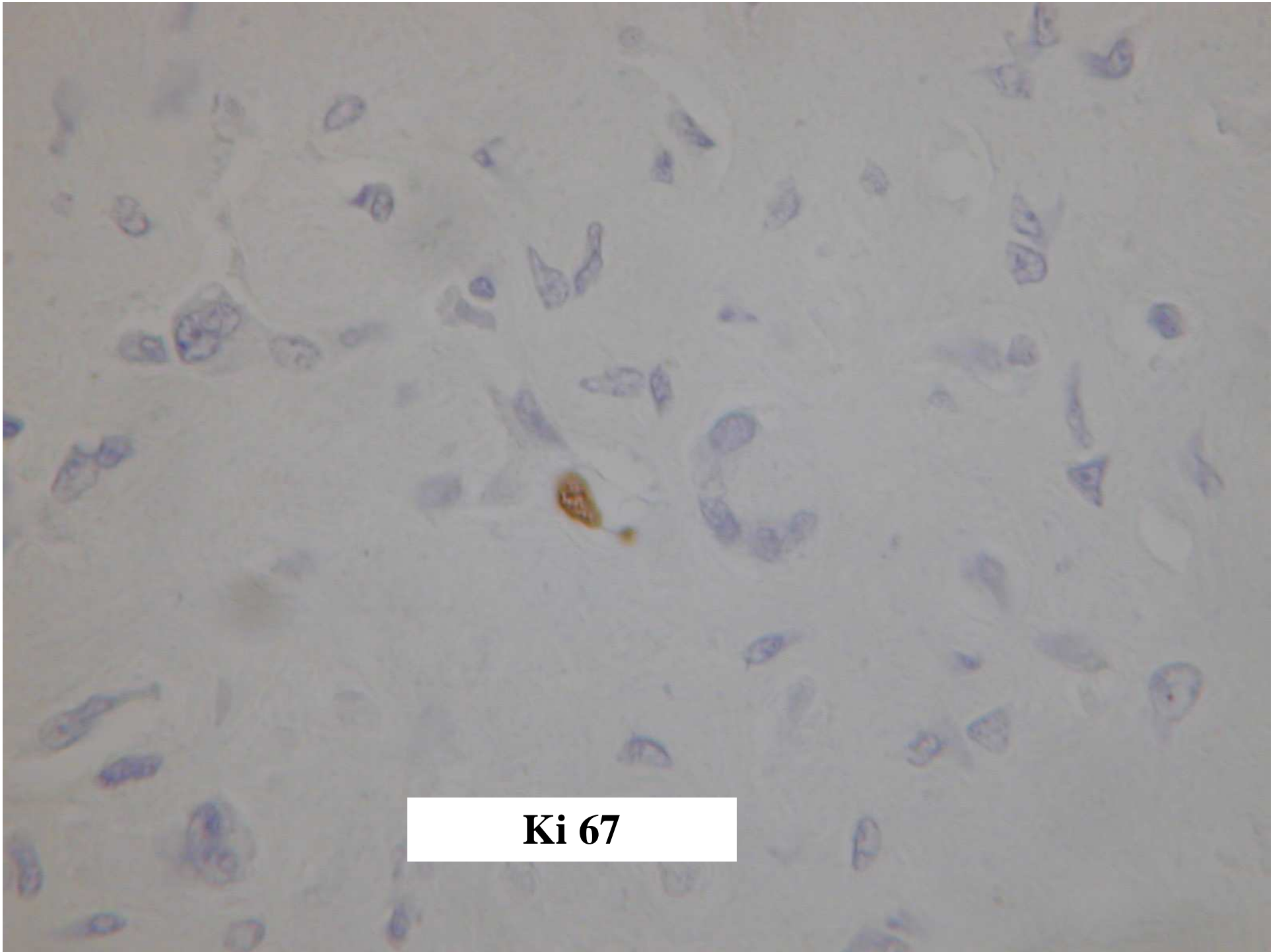
**CD 31**



**BS cytokeratin**



**BS cytokeratin**



**Ki 67**

**Liver Update Meeting – Nottingham Nov 14 2006**

**Diagnosis**

Epithelioid haemangioendothelioma

## Epithelioid haemangioendothelioma - Discussion Points

1. **Characteristic “zonation” (Dietze 1989)**
  - highest cellularity at periphery
    - tectorial growth pattern along sinusoids
    - intravascular “sprouts”
  - obliteration of sinusoids and vessels leads to increasing fibrosis centrally , myxoid stroma, scanty tumour cells
2. **Usually multifocal (>80% of cases, both lobes)**
  - implications for surgical resection
  - lung commonest extrahepatic site of involvement ? metastatic, ? multifocal primary neoplasms
3. **Behaviour unpredictable**
  - low grade malignancy (45-55 % 5 year survival)
  - cellularity, necrosis associated with poor outcome (Makhlouf 1999)
4. **Differential Diagnosis**
  - reactive conditions with zonal fibrosis (including Budd-Chiari syndrome)
  - other neoplasms (esp sclerosing carcinoma)

Makhlouf HR, Ishak KG, Goodman ZD. Epithelioid hemangioendothelioma of the liver: a clinicopathologic study of 137 cases. *Cancer*. 1999; 85:562-82.

Mehrabi et al. Primary malignant hepatic epithelioid hemangioendothelioma: a comprehensive review of the literature with emphasis on the surgical therapy. : *Cancer*. 2006 Nov 1;107(9):2108-21